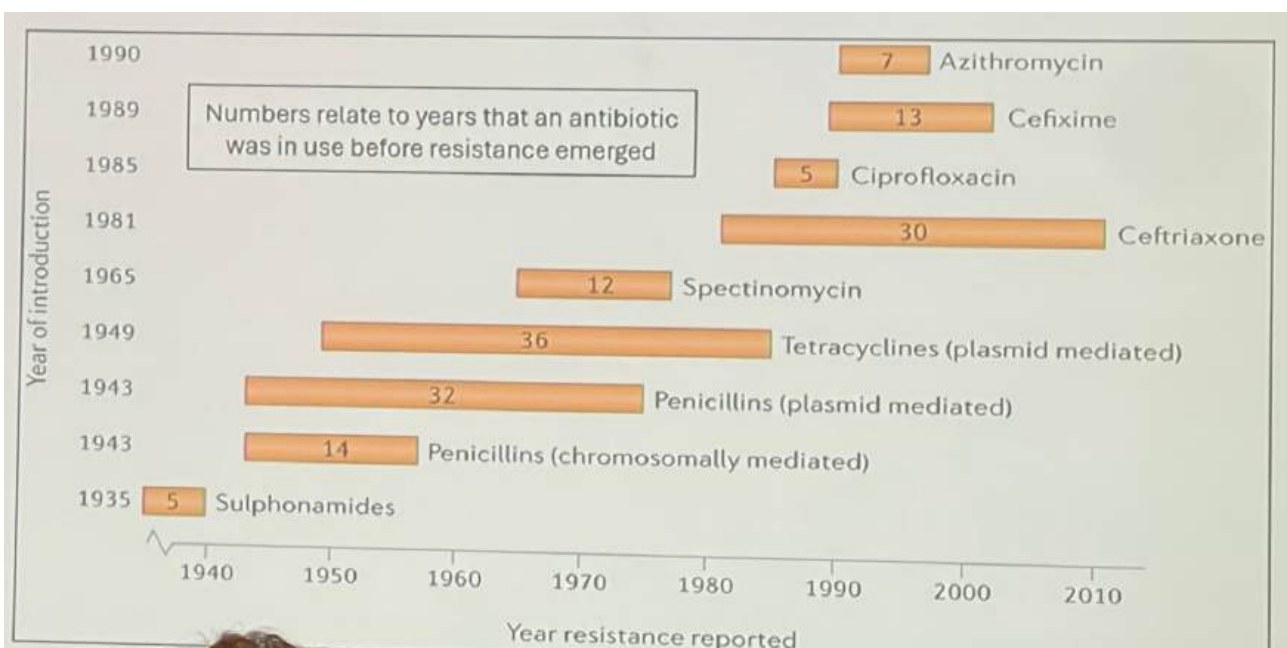



Blandat

- Trikomonas- parauretrala körtlar infekterade, lokal metronidazol fungerar därmed ej.
- PLWH- People Living With HIV
- HIV- Capotegravir (varannan månad) och Lenacapavir (varje halvår)
- Skabb- Spinosad 0,9%- FDA godkänd 2021 mot skabb. Även huvudlöss. Från 4 år, engångsapplicering.
- Ivermektin- ABCB1-mutation, vissa hundar känsliga mot ivermektin, finn även fallrapport människa ABCB1-mutation med neurotoxicitet av ivermektin.

Gonorré

- 4CMenB- Bexsero, aug2025 UK vaccinationsprogram MSM.
- Två nya antibiotika, fas 3-studier, new in class- antibiotics:
 - Gepotidacin- tvådos 12-timmarsintervall
 - Zoliflodacin- singeldos
- Ceftriaxonresistens: 20% Vietnam, 15 % Kambodja, 10 % Kina i flera regioner
- Kromosomal eller plasmidmedierad DNA-överföring

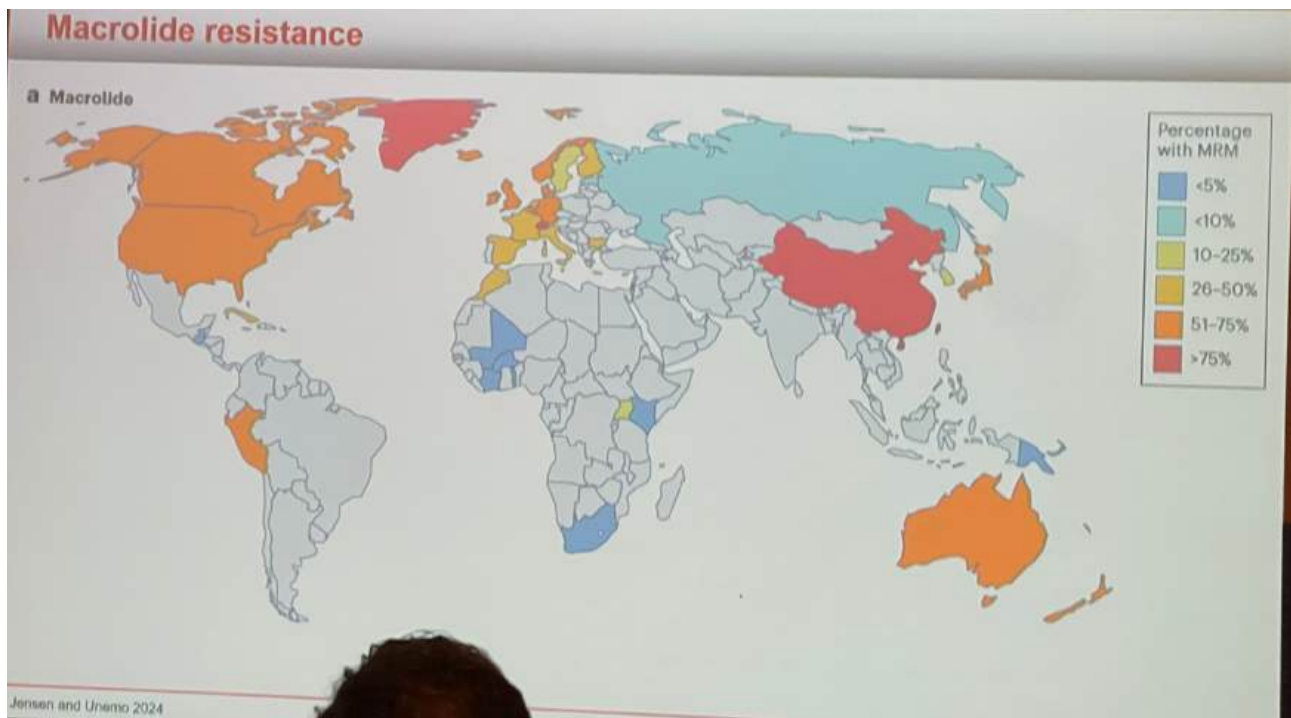


Klamydia

- Lokal Pentamidin (Knapp, K. et al. (2024) Combination of compound screening with an animal model identifies pentamidine to prevent Chlamydia trachomatis infection. Cell Reports Medicine)
- mRNA vaccin (Sanofi) fas 1

Mykoplasma

- Pristinamycin- finns i Frankrike
- Kinolonresistens (QRAM) ej bra prediktor för effekt
- WHO rekommenderar förbehandling med Doxy 100mg x2 7 dagar (conditional recommendation, low certainty in evidence of effects, new 2023)



Third-line treatment

- ❖ Pristinamycin 1 g x 4 for 10 days, 75% cure (Read, 2018)
 - Considered safe in pregnancy
 - Consider combining with doxycycline (non-pregnant)
 - Currently export ban from France
- ❖ Minocycline 100 mg x 2 for 14 days, 70% cure (Clarke 2023)
 - Consider combining with metronidazole 400 mg x 2, 80% cure
 - CNS + GI side effects increase (Htaik, 2025)
- ❖ Sitafloracin 100 mg x 2 for 7 days, 70% cure (GyrA mutations are important)
 - Consider combining with doxycycline 90% cure (Durukan, 2020)
 - Export ban from Japan

M. genitalium potential third or fourth line antimicrobials

- ❖ Pleuromutilins (protein synthesis inhibitors)
 - Lefamulin
 - Very good in vitro activity (Salado-Rasmussen, 2025), but only 50% cure (Ramchandani, 2025)
- ❖ **In vitro susceptibility does not always translate to clinical efficacy**
- ❖ Gyrase/topoisomerase inhibitors
 - Gepotidacin and zoliflodacin
 - Good activity in vitro but no clinical experience (Jensen, 2020; Damião Gouveia, 2018)
- ❖ Nitroimidazoles
 - Metronidazole and tinidazole (Wood, 2023)
 - Promising for combination therapy (Htaik, 2025)

M. genitalium potential third or fourth line antimicrobials

- ❖ Tetracyclines
 - Omadacycline and eravacycline appeared to be less affected by TET MIC
 - Very limited clinical experience with omadacycline (Waltes, 2022)
 - Omadacycline not registered in Europe (application withdrawn)
 - Very expensive (app €450 per day)
 - Eravacycline only available for i.v. with twice-daily infusions
 - Not a viable option on a larger scale

M. genitalium potential third or fourth line antimicrobials

Amphenicols

- Chloramphenicol cured one case (Goodfellow, 2023)
- Thiamphenicol is a safer alternative
 - Has been used for STIs
 - Much better PK/PD properties than CHL

MIC of 53 isolates

- MIC₉₀ = 16 µg/mL and 94% were ≤ 16 µg/mL which is considered the breakpoint
- Possibly some synergy with doxycycline (Skovmand, 2025)

M. genitalium potential third or fourth line antimicrobials

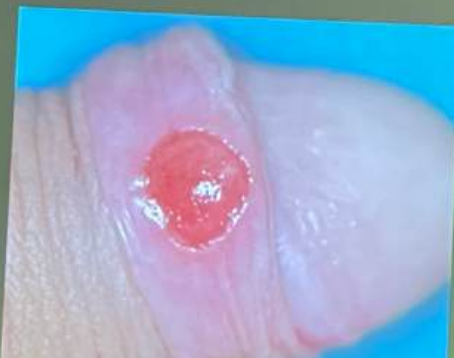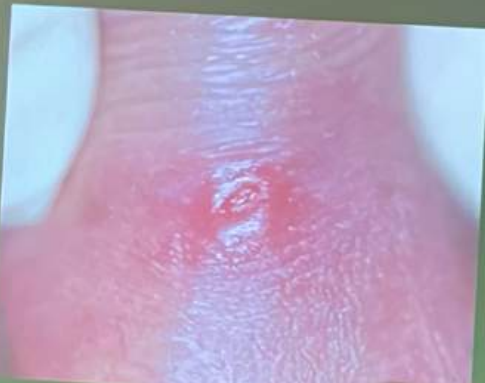- M3P (minocycline, metronidazole, methenamine, pristinamycin) 14/28 days (Vanbaelen, 2025)
 - Successful in 5 cases as salvage

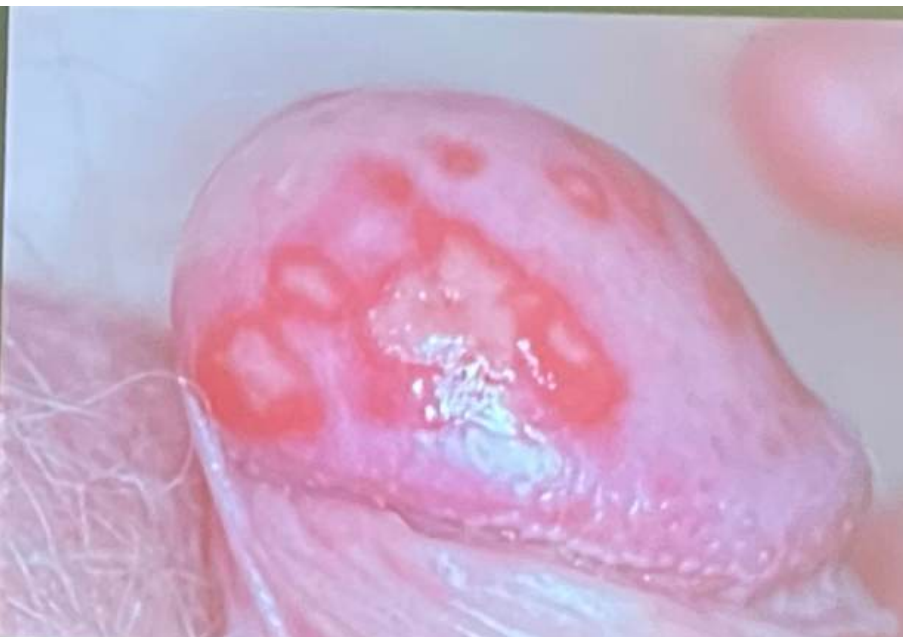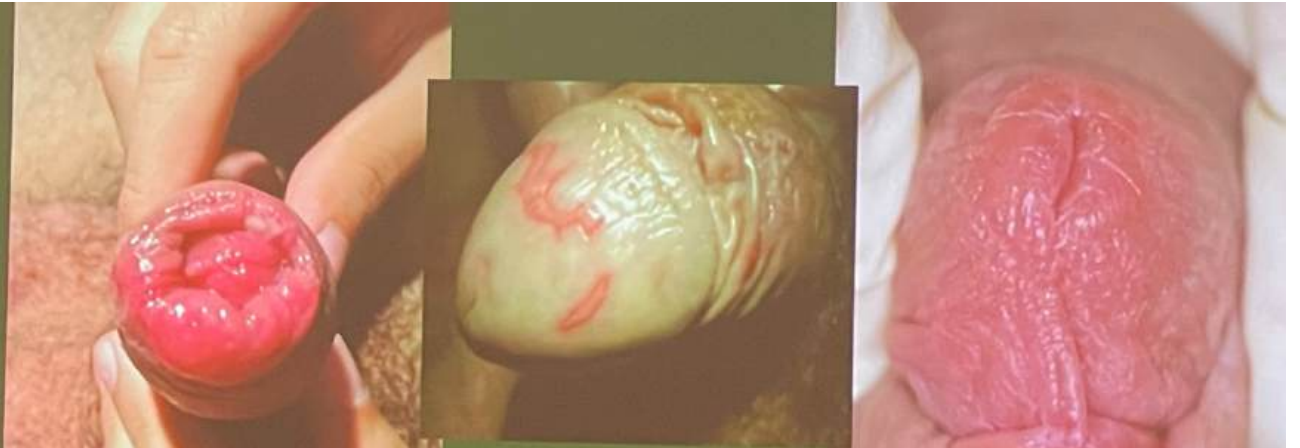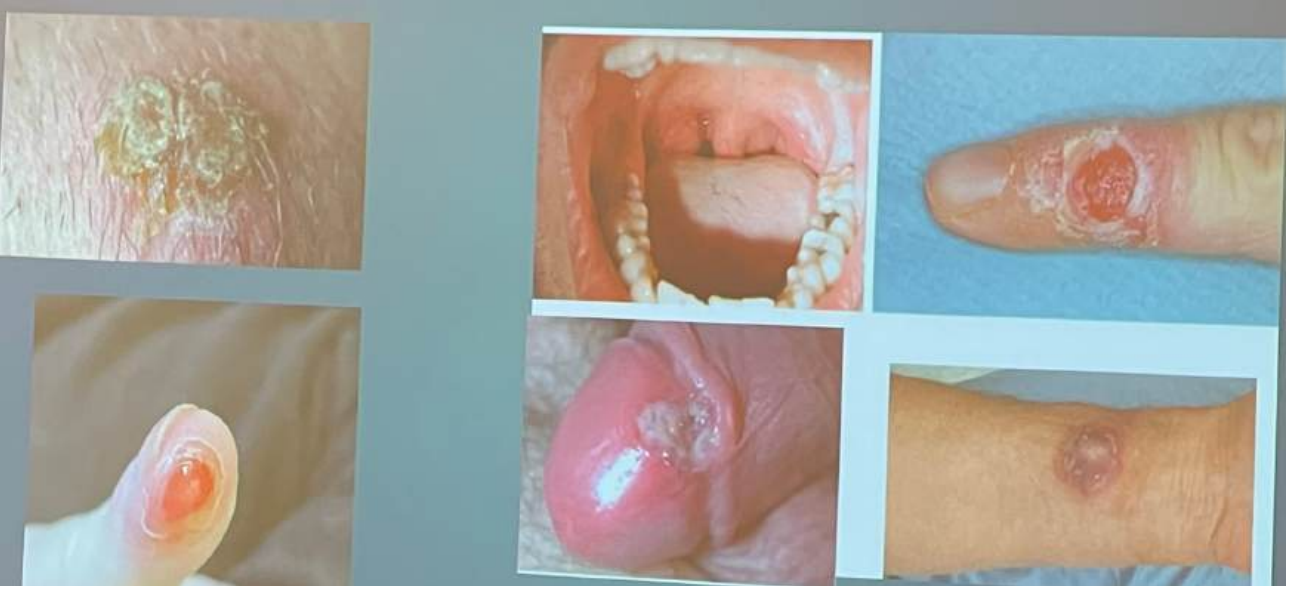Syphilis

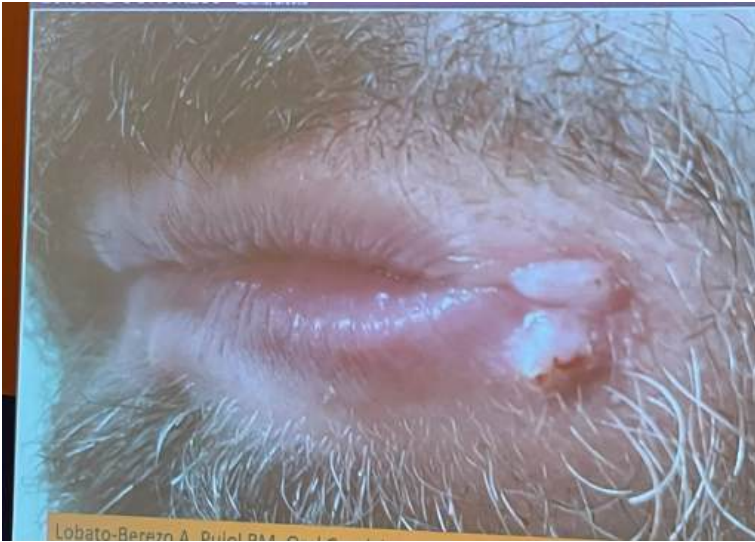- Mörkfältsmikroskopi
- Gömda schankers observandum
- Lymfkörtelförstoringar (ej rektalt)
- "Imitator", men vesikulobullöst bara kongenitalt
- IL10- regulatorisk- gravida, samt de som svarar sämre
- IFNy- proinflammatorisk, högre chans cure
- Bilder på klassisk primär syfilis, sen ovanligare manifestationer av primär och sekundär syfilis, inklusive Follmans balanit (diffus inflammation, multipla ytliga erosioner och purulent exudation före, under eller efter schanker):

Classical primary syphilis

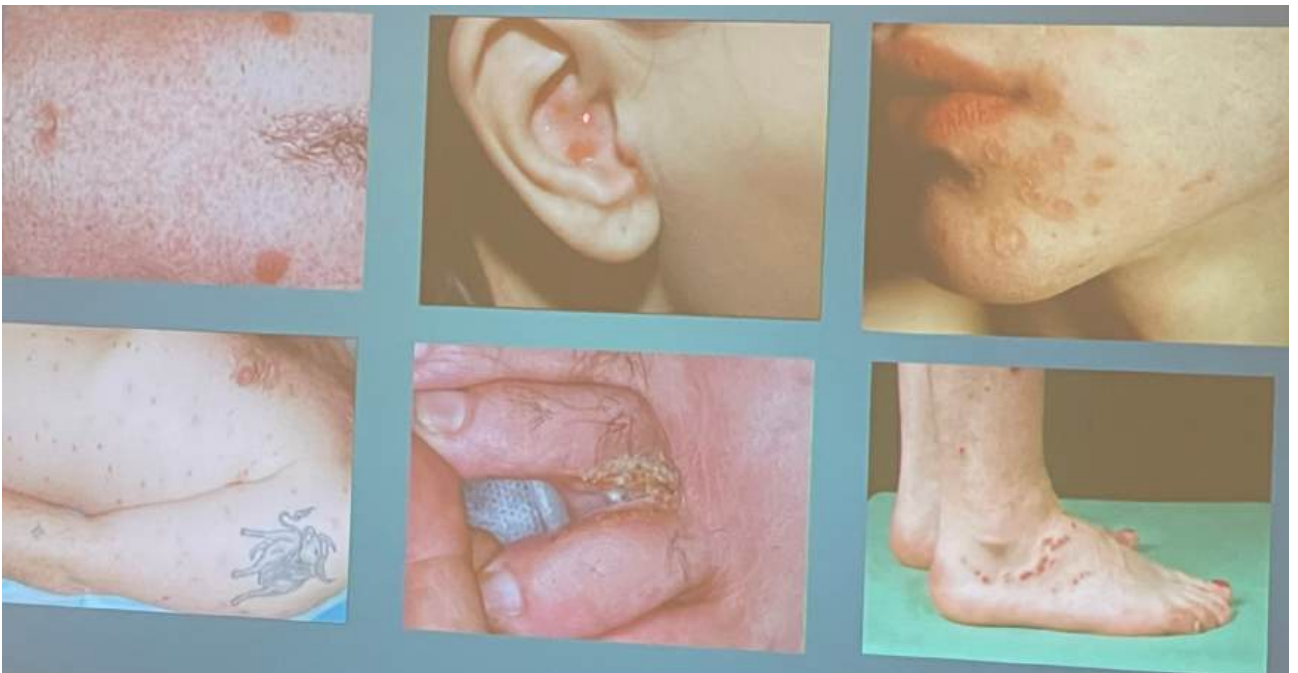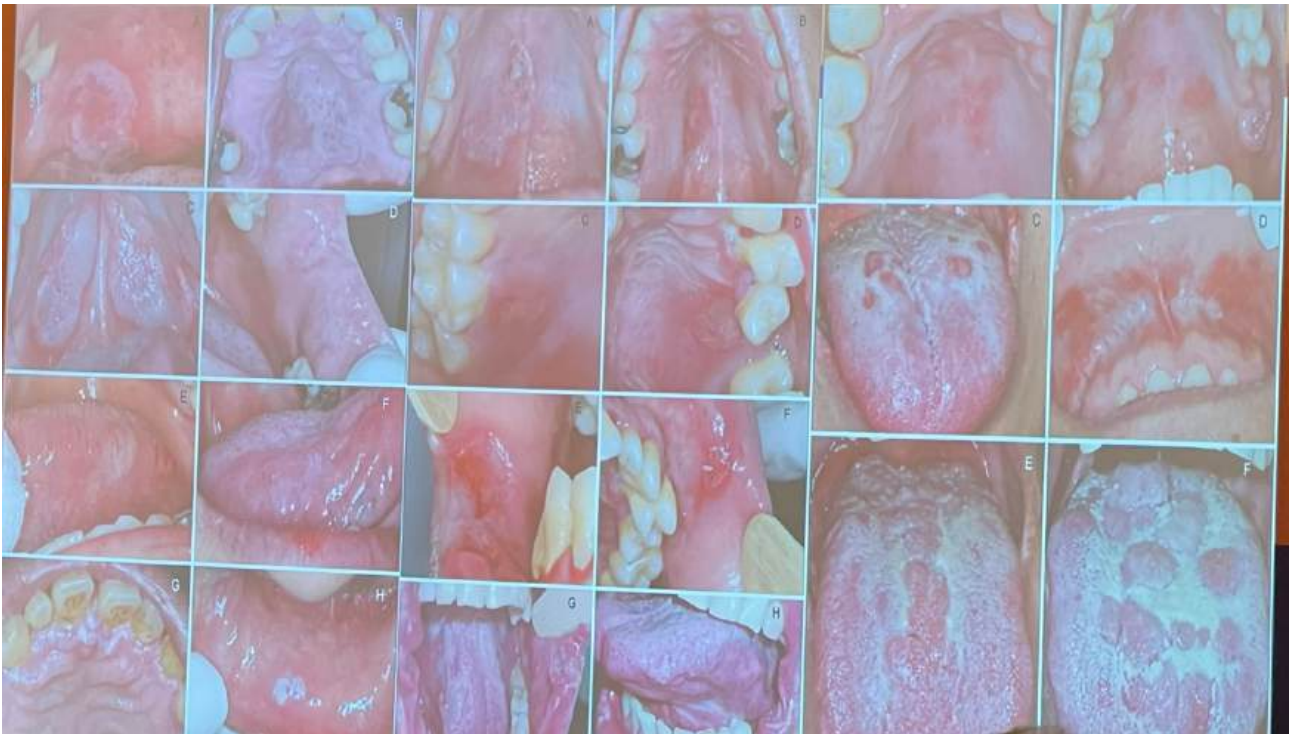- Developing at the genital inoculation site
- Evolving from localized erythema to a painless papule and hard-based ulcer (0.5 – 1.5 cm)





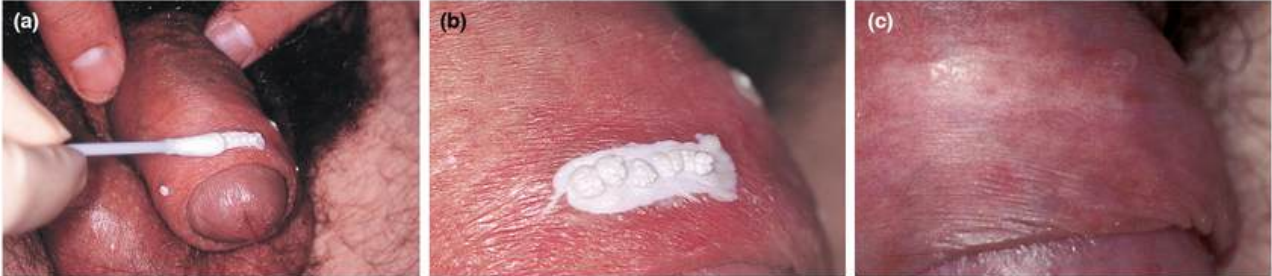

Lobato-Berzo A, Duhal RM, C...



HPV

- Colm O'Mahony- TCA 90%, alt kryo. Sen Aldara.
- AHCC, Shiitake-svamp (jmf Veregen)
- C. O'Mahony, et al, (2019). *Position statement for the diagnosis and management of anogenital warts. JEADV*



AI

- Aysa, Visual DX, Skinive AI

8th IUSTI Sexual health from Hippocrates to AI
EUROPE CONGRESS October 9-11 2025 Athens, Greece

Current Trends and Future Directions of Digital Pathology and Artificial Intelligence in Dermatopathology: A Scientometric-Based Review

- Whole Slide Imaging (WSI) enables full digital workflows and remote diagnostics
- Benefits:
 - Faster diagnosis
 - Improved collaboration
 - Enhanced education and research
- Limitations:
 - High implementation cost
 - Lack of interoperability
 - Validation gaps
- AI assists in pre-screening, region detection and preliminary diagnosis
- Applications:
 - Tumor classification
 - Mitosis counting
 - Metastatic differentiation
- Challenges:
 - Transparency
 - Reproducibility
 - Ethical and legal responsibility

Cocuz, Iuliu Gabriel et al., *Diagnostics (Basel, Switzerland)* vol. 15, 29 Aug. 2025.

Pigeons as Trainable Observers of Pathology and Radiology Breast Cancer Images

- Pigeons can learn complex medical image discrimination tasks
- Demonstrate generalization and adaptive visual learning
- Highlight parallels between avian and human image cognition
- Serve as models for studying visual perception and training AI systems
- Potential tool for advancing medical imaging research and education



Levenson, Richard M et al, *PloS one* vol. 10, 18 Nov. 2015

Herpes

- Herpes-PrEP med aciklovir/valaciklovir fungerar ej (då de påverkar replikation men ej infektion).
- Aciklovir
 - Resistent HSV kan vara känslig för högdos
 - Absorberas i övre GI, obs gastric bypass
 - Kan man ej överdosera
- UK nya guidelines gravida
 - Suppressionsbehandling gravida i vissa fall
 - Neonatal herpes anmälningskyldig
- Helical primase inhibitor
 - Pritelivir
 - Amenamevir- även aktivitet HZV, 400 mg upptill 30 dagar, Japan, mer än en miljon människor redan behandlade.
 - IM 250- djurstudier latent reservoir minskar.

Candidavulvovaginit

- Peter Greenhouse- slumpmässiga återfall, följ guideline, annars "think hormones":
- Hormonal cycle supression treatment/ Catamenial candida
 - Symtomatisk i lutealfas- premenstruell
 - Flukonazol 2-3 d före symtom, 150mg x 1 (ev upprepa efter 4-5 dagar), eller hormonell lösning
 - Finns ej i nån guideline (Detroit, BASHH, Farr, Donders), ges då varje vecka ist för varje månad
- Probiotika- oklar evidens
- Diet- ej evidens

Mikrobiom

- Manlig mikrobiom- Prevotella ökar risk HIV och HPV
- Lactobacillus crispatus- eubios
- L. iners- dysbios